

INTERRUPTED AORTIC ARCH IN CHILDREN: AN IN-DEPTH LOOK AT ETIOLOGY, EMBRYOLOGICAL MECHANISMS, AND MORPHOLOGY (A LITERATURE REVIEW)

*Zh.A. Moldakhanova¹, R.I. Rakhimzhanova², T.B. Dautov^{1,2},
L.A. Bastarbekova¹, B.B. Kaliyev³*

¹“National research Cardiac Surgery center” NCJSC, Astana, the Republic of Kazakhstan;

²“Astana Medical University” NCJSC, Astana, the Republic of Kazakhstan;

³«National Scientific Center for Mothers and Children» NCJSC, Astana, the Republic of Kazakhstan;

ABSTRACT

Relevance: Congenital heart defects (CHD) account for one-third of all congenital malformations and occur in 0.7-1.7% of newborns. Interrupted aortic arch (IAA) is quite rare, accounting for 1% of CHD. IAA is an unusual shape of critical neonatal heart disease in which there is a lack of continuity between the ascending aorta and the descending thoracic aorta. IAA is almost always severe in the neonatal period and requires urgent corrective surgery.

This study aimed to identify gaps in knowledge, suggest directions for in-depth research through critical analysis, and improve our understanding of risk factors and mechanisms of embryology that contribute to aortic arch interruption to improve the approach to diagnosis and treatment.

Materials and Methods: A literature search was conducted in electronic databases PubMed, MEDLINE, Web of Science, Google Scholar, and e-library. The review covered 20 sources meeting the inclusion criteria.

Results: We systematize the available literature data on embryology and risk factors to improve the IAA diagnosis and treatment approach. We found that aorta development begins at Week 3 of pregnancy, and the main factor in further IAA etiology is the chromosomal deletion 22q11.2.

Conclusion: Understanding the timeline during early embryonic development plays a critical role in aortic arch formation. Abnormalities occurring in this period, such as chromosomal deletions, may contribute to IAA. This finding highlights the importance of genetic factors in the etiology of this condition and the potential for genetic screening and counseling for individuals with chromosomal abnormalities, especially those in the 22q11.2 region.

Keywords: congenital heart defect (CHD), anatomy, interrupted aortic arch (IAA), epidemiology.

ПЕРЕРЫВ ДУГИ АОРТЫ У ДЕТЕЙ: УГЛУБЛЁННЫЙ ВЗГЛЯД НА ЭТИОЛОГИЮ, ЭМБРИОЛОГИЧЕСКИЕ МЕХАНИЗМЫ И МОРФОЛОГИЮ (ОБЗОР ЛИТЕРАТУРЫ)

*Ж.А. Молдаханова¹, Р.И. Рахимжанова², Т.Б. Даутов^{1,2},
Л.А. Бастарбекова¹, Б.Б. Калиев³*

¹НАО «Национальный научный кардиохирургический центр», Астана, Республика Казахстан;

²НАО «Медицинский университет Астана», Астана, Республика Казахстан;

³НАО «Национальный Научный Центр Материнства и Детства», Астана, Республика Казахстан

АННОТАЦИЯ

Актуальность: Врожденные пороки сердца (ВПС) составляют треть всех врожденных пороков развития и встречаются у 0,7-1,7% новорожденных. Перерыв дуга аорты (ПДА) встречается довольно редко, составляя 1% ВПС. ПДА является редкой формой критического неонатального порока сердца, при котором отсутствует преемственность между восходящей аортой и нисходящей грудной аортой. ПДА почти всегда протекает тяжело в неонатальном периоде и требует срочной корректирующей операции.

Цель исследования – выявление пробелов в знаниях, предложение направлений для углубленного исследования посредством критического анализа и улучшение нашего понимания факторов риска, механизмов эмбриологии, которые способствуют прерыванию дуги аорты, для совершенствования подхода к диагностике и лечению.

Материалы и методы: Поиск литературы осуществлялся в электронных базах данных PubMed, MEDLINE, Web of Science, Google Scholar и электронной библиотеке с использованием ключевых слов. В анализ были включены 20 источников, которые соответствовали критериям включения.

Результаты: Были систематизированы имеющиеся литературные данные по эмбриологии и факторам риска для совершенствования подхода к диагностике и лечению ПДА. Авторы обнаружили, что развитие аорты начинается на 3 неделе беременности, и основным фактором дальнейшей этиологии является хромосомная делеция 22q11.2.

Заключение: Понимание временной шкалы во время раннего эмбрионального развития играет решающую роль в формировании дуги аорты. Аномалии, возникающие в этот период, такие как хромосомные делеции, могут способствовать развитию ПДА. Этот вывод подчеркивает важность генетических факторов в этиологии этого состояния и потенциал для генетического скрининга и консультирования людей с хромосомными аномалиями, особенно в области 22q11.2.

Ключевые слова: врожденный порок сердца (ВПС), анатомия, перерыв дуги аорты (ПДА), эпидемиология.

БАЛАЛАРДАҒЫ АОРТА ДОҒАСЫНЫҢ ҮЗІЛУІ: ЭТИОЛОГИЯҒА, ЭМБРИОЛОГИЯЛЫҚ МЕХАНИЗМДЕРГЕ ЖӘНЕ МОРФОЛОГИЯҒА ТЕРЕҢ ШОЛУ (ӘДЕБИЕТКЕ ШОЛУ)

**Ж.А. Молдаханова¹, Р.И. Рахимжанова², Т.Б. Даутов^{1,2},
Л.А. Бастарбекова¹, Б.Б. Калиев³**

¹«Ұлттық ғылыми кардиохирургия орталығы» КЕАҚ, Астана, Қазақстан Республикасы;

²«Астана медицина университеті» КЕАҚ, Астана, Қазақстан Республикасы;

³«Ұлттық ана мен бала ғылыми орталығы» КЕАҚ Астана, Қазақстан Республикасы

АНДАТПА

Өзектілігі: Туа біткен жүрек ақауы (ТБЖА) барлық туа біткен кемістіктердің үштен бір бөлігін құрайды және жаңа туған нәрестелердің 0,7-1,7%-ында болады. Аорта доғасының үзілуі (АДҮ) өте сирек кездеседі, оның үлесіне ТБЖА-ның 1%-ы тиесілі. АДҮ — көтеріңкі қолқа мен кеміп келе жатқан торақалды қолқа арасында сабақтастықтың жоқтығы байқалатын жүректің неонаталдық ақауының жиі кездесетін пішіні. АДҮ неонаталдық кезеңде әрдайым дерлік ауыр болады және шұғыл түзету операциясын талап етеді.

Зерттеудің мақсаты – олқылықтарды анықтауға, сыни талдау арқылы терең зерттеу бағыттарын ұсынуға және аорта доғасының үзілуіне ықпал ететін қауіп факторлары, эмбриология механизмдері туралы түсінігімізді жақсартуға, диагностика мен емдеуге көзқарасты жақсартуға бағытталған.

Материалдар мен әдістер: Әдістер: Әдебиетті іздеу PubMed, MEDLINE, Web of Science, Google Scholar және e-library электрондық дерекқорларында кілт сөздерді пайдалана отырып жүргізілді. Талдауға қосу критерийлеріне сай келетін 20 дереккөз енгізілді.

Нәтижелері: АДҮ диагностикасы мен емдеу тәсілін жақсарту үшін эмбриология және қауіп факторлары туралы әдебиеттің қолда бар деректерін жүйелейміз. Аортаның дамуы жүктіліктің 3 аптасынан басталатынын анықтадық, ал одан әрі АДҮ этиологиясының негізгі факторы хромосомалық жою 22q11.2 болып табылады.

Қорытынды: Ерте эмбриондық даму кезіндегі уақыт шкаласын түсіну қолқа аркасының қалыптасуында маңызды рөл атқарады. Осы кезеңде орын алған ауытқулар, мысалы, хромосомалық жоюлар АДҮ-ға ықпал етуі мүмкін. Бұл қорытынды осы жағдайдың этиологиясындағы генетикалық факторлардың маңыздылығын және хромосомалық ауытқулары бар адамдарға, әсіресе 22q11.2 өңірдегі адамдарға генетикалық скрининг және кеңес беру әлеуетін көрсетеді.

Түйінді сөздер: туа біткен жүрек ақауы (ТБЖА), анатомия, аорта доғасының үзілуі (АДҮ), эпидемиология.

Introduction: Congenital heart defects (CHDs) account for a third of all congenital malformations and 17.9 per 1,000 newborns worldwide. Interrupted aortic arch (IAA) is quite rare, accounting for 1% of all CHD cases. IAA is a defect dependent on the patent ductus arteriosus, as it is the only way blood flow can move to places far from the rupture. In 1778, it was first described by Steidel, and then in 1959, it was classified into three types by Celoria and Patton [1]. Without treatment, the average age of patients is 4-10 days [2], usually after the physiological closure of the patent ductus arteriosus. However, fortunately, mortality from CHD decreased by 34.5% worldwide between 1990 and 2017, mainly due to the rapid development of diagnostic imaging, drugs, and accumulated surgical experience, and therefore improved postoperative survival, often requiring further intervention to eliminate the aortic arch residual or recurrent obstruction [3]. Congenital anomalies and variations of the aortic arch range from asymptomatic variations, mostly detected by chance, to clinically symptomatic variations that cause respiratory distress syndrome or esophageal compression [4]. Radiologists and clinicians should be aware of the options for IAA because they can have important consequences in diagnosis and classification, the choice of treatment tactics in managing patients, and further prognosis. IAA is a complex congenital cardiovascular malformation characterized by a lack of luminal continuity between the ascending and descending thoracic aorta. Also, an additional displacement of the posterior conical septum to this defect, leading to a defect in the interventricular septum as a concomitant defect, is present in approximately 73% of all cases. In addition to the defect of the interventricular septum, IAA can be associated with other more complex cardiac anomalies; for example, transposition of the main arteries, arterial trunk, aortopulmonary window, single ventricle, atresia of the aortic valve, double outlet right ventricle. Due to the incorrect location of the septum, there may also be an obstruction of the outflow tract of the left ventricle, which was previously considered the etiology of this defect. However, more recent evidence shows multiple genetic disorders associated with IAA, such as microdeletion of chromosome 22q11 or Di George syndrome, present in 50% of patients with IAA. It is currently the most well-known etiology of this defect [5]. This review will describe the embryological development and anatomy of the thoracic aorta and discuss the types and comorbidities of IAA.

This study aimed to identify knowledge gaps, suggest directions for deep research through critical analysis, and enhance our understanding of the anatomical factors contributing to interrupted aortic arch to better the approach to diagnosis and treatment.

Materials and Methods: A literature search was carried out in electronic databases PubMed, MEDLINE, Web of Science, Google Scholar, and e-library, using keywords. The review included 18 full-text articles published in English or Russian over the past decade and excluded duplication or repetition of information and media articles.

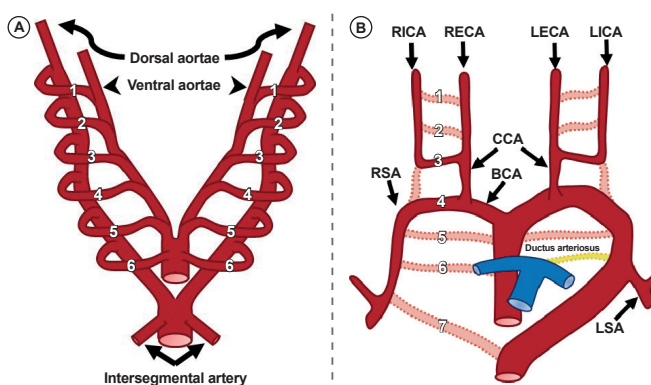
The review selected important publications and represented the aspects of the issue. Following the analysis of the article abstracts, the full-text versions of the associated articles were included in the Mendeley database and verified for duplication.

Results:

Embryology

Understanding the normal development of the aortic arch is essential to understanding and classifying the various subtypes of aortic arch anomalies and variants. Two distinct developmental models can explain the development of the great vessel system. The development of the aorta begins on Week 3 and is completed by Week 8 of pregnancy. The system of main arteries, including the aortic arch, arises from six pairs of pharyngeal arch arteries, each of which connects the dorsal and ventral primitive aorta. These

primitive arches appear separately, regress, and eventually reconstruct and transform into parts of the large vessel system, including the aortic arch, arch branches, ductus arteriosus, and proximal segments of the pulmonary arteries. This embryological model was originally proposed in Rathke's classic diagram (Fig. 1). The primitive first and second arcs regress with the first, and the residual areas become maxillary, sublingual, and stirrup arteries. The primitive fifth aortic arch usually regresses but may rarely persist as a double aortic arch [6]. A mature system of aortic arches forms as some of the primitive arcs regress while others persist and develop. After some arches regress, the remains of the third, fourth, and sixth primitive arcs give rise to mature large vessels. The third arch becomes the common carotid and proximal internal carotid arteries, and the fourth arc forms the terminal arch of the mature aorta. The primitive sixth arch is preserved as a segment of the pulmonary arteries and arterial duct. The mechanism for determining the persistence or regression of segments of the aortic arch is not fully known [5, 6].



Legend: BCA – brachiocephalic artery, CCA – common carotid artery, LECA – left external carotid artery, LICA – left internal carotid artery, LSA – left subclavian artery, RECA – right external carotid artery, RICA – right internal carotid artery, RSA – right subclavian artery

Figure 1 – Schematic representation of a Rathke diagram: A – pair of intersegmental arteries (straight arrows) arises from the aortic sac; B – schematic representation of normal aortic arch and branch vessels development [3]

The transverse arch of the aorta is formed from the left fourth arch of the aorta (Fig.1 A). Six paired branchial arches (numbered 1 to 6) connect the paired ventral aortae (arrowheads) and dorsal aortae (curved arrows). A pair of intersegmental arteries (straight arrows) arises from the aortic sac (Fig.1 B). Selective involution of the branchial arch segments results in the final adult aortic arch and is thought to be the main mechanism underlying arch and branch vessel anomalies [3]). Abnormalities in the left fourth aortic arch formation lead to aortic arch break types B and C. Type A IAA is essentially the most severe form of aortic coarctation and is likely associated with conditions that result in decreased fetal left ventricular exit and, therefore, decreased flow through the aortic isthmus, including obstruction of the left ventricular outflow tract. Type B IAA occurs almost exclusively in combination with a posterior deviation of the septum, leading to a violation of the septum and a narrowing of the outflow of the left ventricle [6]. The aortic valve is often bicommissural (at least 30% of all IAAs) and may have varying degrees of hypoplasia. IAA is most commonly found in the left-sided aortic arch but can also occur in the right aortic arch [7].

Etiology

All newborns with IAA are identified when the patent ductus arteriosus closes within the first two weeks after birth. The exact etiologies of IAA have yet to be elucidated, but IAA can be considered a phenotype of heterogeneous etiologies. For example, approximately 50–80% of patients with type B IAA have a genetic etiology, such as Di George syndrome and chromosome deletion of 22q11 [8]. In 1968, Di George described a small group of patients identified in immunology clinics with distinct facial features, thymus hypoplasia or aplasia, parathyroid hypoplasia, and CHD. Cytogenetic and molecular analysis of patients with Di George syndromes and conotruncal facial abnormalities showed that almost 90% of such patients had a common genetic etiology, namely microdeletion of chromosome 22q11.2 [9]. 22q11.2DS is an autosomal dominant syndrome of deletion of adjacent genes. Descendants of patients have a 50% chance of inheriting the 22q11.2 deletion. The 22q11.2 deletion syndrome is the most common, occurring in about 1 in 4 to 6,000 live births. It is one of the most common chromosomal changes associated with congenital heart disease. The spectrum of CHDs associated with 22q11.2DupS has been described in only a few studies. CHD is less common among patients with 22q11.2DupS compared to patients with 22q11.2 deletion syndrome (22q11.2DelS) and is more diverse, including aortic arch-deluge conotruncal defects, septal defects, and left-sided obstructive lesions. Earlier studies in hospitals reported that 75–80% of patients with a score of 22q11.2 had CHD. The main clinical manifestations of 22q11.2DS include CHDs, especially malformations of conotruncus (defect of the interventricular septum, Tetralogy of Fallot, IAA, and common arterial trunk) [10]. Maternal factors such as advanced maternal age, maternal diabetes, and exposure of the mother to teratogenic agents during pregnancy are suggested potential risk factors for IAA. Maternal health and prenatal care are critical in reducing the likelihood of congenital heart anomalies, including IAA [11]. Certain infections during pregnancy, such as rubella, have been associated with an increased risk of congenital heart defects, including IAA. Additionally, exposure to environmental toxins or medications during critical periods of fetal development may contribute to the development of these anomalies [12]. The transverse aortic arch protrudes from the left quarter of the aortic arch, and abnormalities in the left quarter of the aortic arch are responsible for type B and type C IAA. Type A IAA is essentially the most severe form of aortic coarctation and is likely associated with the condition that leads to the development of fetal left ventricular exit and therefore to decreased flow through the aortic isthmus, including obstruction of the left ventricular outflow pathway.

Epidemiology

According to the latest epidemiological data, the incidence of IAA varies depending on the population studied, with rates ranging from 0.1 to 3.7 per 10,000 live births. The prevalence of IAA is generally low, estimated to be less than 1 per 10,000 live births.

Mortality

Infants with IAA are at high mortality risk, particularly if the defect is not diagnosed and treated promptly. The reported mortality rate for untreated IAA is approximately 90%, and even with prompt treatment, the mortality rate remains high (approximately 30%) [13].

Risk factors: The etiology of IAA is not fully understood, but some risk factors have been identified. These include chromosomal abnormalities (such as DiGeorge syndrome), maternal diabetes, and exposure to certain medications or toxins during pregnancy [14].

According to a retrospective study published in the *Journal of Pediatric Surgery* in 2019, aortic arch rupture is a rare but severe complication of aortic coarctation repair in children, with an estimated incidence of 0.15% (9/5947) in the study

population. The study also found that aortic arch rupture was associated with a high mortality rate (67%) and that younger age and low weight at surgery were risk factors for developing this complication.

Associated Conditions

Most (~95%) cases are associated with septal defects. The risk of mortality in IAA is increased due to the associated complex abnormalities. A more commonly associated heart defect with IAA is a defect in the interventricular septum. Posterior deviation of the conal septum (relative to the ventricular septum) leads to improper alignment of the VSD (ventricular septal defect) and can contribute to hemodynamically significant obstruction of the excretory tract of the left ventricle. Other anatomical features that may contribute to obstruction of the left ventricular excretory tract include the hypoplastic aortic ring and/or bicuspid aortic valve with commissural fusion and the bulge of the Moulart muscle (a bundle of muscles protruding from the wall of the left ventricle to the excretory tract of the left ventricle). A clinically significant atrial septal defect is more common in the form of a stretched (or large) patent foramen ovale. Various sporadic ventricular heart defects occur in 11% of patients with IAA. The development of a hemodynamically significant subaortic membrane may also occur within 1–2 years after surgical correction of IAA in newborns [14].

The conal septum is deflected posteriorly in almost all cases of type B IAA, which leads to VSD and narrowing of the outflow of the left ventricle. Type B IAA combined posterior deviation septum in 30% have a bicommissural aortic valve. A typical phenomenon, especially in type B IAA with concomitant Di George syndrome, is the aberrant right subclavian artery [15]. The aberrant right subclavian artery develops on the right side of the proximal descending aorta near the beginning of the left subclavian artery. The aortopulmonary window, a defect in the interventricular septum, or the transposition of the main arteries are more often associated with a type A break [16].

K. Friedman conducted a systematic review to examine the literature on the description of the embryology and anatomy of the aortic arch system and found that the aberrant right subclavian artery is common in type B with VSD and is associated with a worse outcome. The proposed mechanism for worse outcomes is that there is less outflow of the left ventricle and ascending aorta during the life of the fetus since the aberrant subclavian is distal to the patent ductus arteriosus (PDA) and, therefore, blood circulation goes through the IAA [15].

Hemodynamics

Physiology in IAA depends in part on associated heart disease. Regardless of concomitant lesions, lower extremity blood flow depends on the type of IAA. Normally, the fetal right ventricle provides most of the lower body circulation, with only 10% of the combined fetal cardiac output crossing the aortic isthmus. Thus, it is not surprising that the fetus tolerates IAA well. After birth, the IAA usually closes within the first week of life, resulting in lower body hypoperfusion and enlargement after left ventricular exercise, followed by metabolic acidosis, renal failure, left ventricular dysfunction, and circulatory collapse [17].

Classification

According to the Celoria and Patton classification, IAA can be grouped into three types, depending on the site of the disruption [2]:

Type A: The disruption is located distal to the left subclavian artery; the second most common disruption represents approximately 13% of the cases.

Type B: The disruption is located between the left carotid artery and the left subclavian artery; this is the most common anomaly, representing approximately 84% of the cases.

Type C: The disruption is located between the innominate artery and the left carotid artery; this rare type represents approximately 3% of all cases.

These three types of IAA can be sub-classified according to the origin of the subclavian artery:

Type 1: Normal origin of the subclavian artery.

Type 2: Aberrant right subclavian artery, found distal to the left subclavian artery.

Type 3: Isolated right subclavian artery; found originating from a right patent ductus arteriosus.

In IAA type A, the arch is interrupted distal to the left subclavian artery's origin. This anomaly is thought to be caused by an abnormal regression of a part of the left fourth arch at the end of development after the left subclavian artery has relocated to its normal position. Type A is the second most common type of IAA. It affects 30–40% of people with IAA [18].

In IAA type B, the arch is interrupted depending on where the left common carotid and the left subclavian arteries start. Type B is the most common type of IAA, accounting for 50–60% of cases. More than half of the time, IAA type B is associated with 22q11.2 microdeletion and other features outside the heart. Type B is often part of specific syndromes, such as DiGeorge's syndrome.

In type C IAA, the arch is ruptured between where the brachiocephalic artery and the left common carotid artery start. This anomaly is thought to be caused by the ventral part of the left third and fourth arches moving backward in an unusual way. Type C is the rarest form of IAA, making up less than 5% of cases [19].

Thus, it has been established that it is necessary to study the anatomical and morphological features of this defect for the diagnosis and development of treatment tactics in the pediatric population, and it is necessary to take into account the type and localization of the defect, which plays an important role in the outcome of this defect. This study showed that the aorta development starts on Week 3 of pregnancy, and the 22q11.2 chromosomal deletion is the main factor for the future disease etiology. Patient survival depends on the severity, time of diagnosis, and treatment of congenital heart disease. Factors associated with mortality include low birth weight [20].

Discussion: The presented article provides a comprehensive overview of the interrupted aortic arch (IAA), its embryological development, anatomy, associated conditions, and risk factors. It also highlights the importance of accurate diagnosis and timely management to improve patient outcomes. Overall, the article presents valuable insights into the understanding of IAA and offers suggestions for further research to enhance our knowledge in this field. The discussion of the embryological development of the aortic arch and the associated abnormalities leading to IAA provides a solid foundation for understanding the pathogenesis of this congenital heart defect. The description of Rathke's classic diagram and the transformation of primitive arches into mature large vessels is informative. The discussion emphasizes the significance of the left fourth aortic arch in forming the transverse arch of the aorta and its relation to type B and type C IAA. Understanding these anatomical factors is crucial for accurately diagnosing and classifying the different subtypes of IAA. The article highlights the role of genetic factors in the etiology of IAA, particularly the association with DiGeorge syndrome and microdeletion of chromosome 22q11.2. This section focuses on the importance of genetic testing and evaluation in patients with IAA, as it may influence treatment decisions and prognosis. The article effectively discusses the commonly associated heart defects with IAA, particularly the defect in the interventricular septum, and the impact of these conditions on the hemodynamics of the heart. The discussion highlights the complexity of IAA and the need for a comprehensive approach to managing patients with multiple coexisting anomalies. According to Celoria and Patton, the classification of IAA is well-described, along with the subtypes based on the origin of the subclavian artery.

Conclusion: The embryological development of the aortic arch is discussed, starting from Week 3 of pregnancy, involving six pairs of pharyngeal arch arteries that eventually form the aortic arch and related structures. Abnormalities during this process, like chromosomal deletion 22q11.2, are linked to IAA, emphasizing the importance of genetic factors in its etiology.

The article also discusses the classification of IAA into three types (A, B, and C) based on the disruption site, associated conditions, and risk factors. Timely diagnosis and management are crucial, as untreated IAA can have a mortality rate of approximately 90%.

REFERENCES:

1. Burbano-Vera N., Zaleski K.L., Latham G.J., Nasr V.G. Perioperative and anesthetic considerations in interrupted aortic arch // *Semin. Cardiothorac. Vasc. Anesth.* – 2018. – Vol. 22(3). – P. 270-277. <https://doi.org/10.1177/1089253218775954>
2. Andrianova E.I., Naimo P.S., Fricke T.A., Robertson T., Bullock A., Brink J., d'Udekem Y., Brizard C.P., Konstantinov I.E. Outcomes of interrupted aortic arch repair in children with biventricular circulation // *Ann. Thorac. Surg.* – 2021. – Vol. 111(6). – P. 2050-2058. <https://doi.org/10.1016/j.athoracsur.2020.05.146>
3. Bae S.B., Kang E.J., Choo K.S., Lee J., Kim S.H., Lim K.J., Kwon H. Aortic arch variants and anomalies: embryology, imaging findings, and clinical considerations // *J. Cardiovasc. Imaging.* – 2022. – Vol. 30(4). – P. 231-262. <https://doi.org/10.4250/jcvi.2022.0058>
4. Scott M., Neal A.E. Congenital heart disease // *Prim. Care.* – 2021. – Vol. 48(3). – P. 351-366. <https://doi.org/10.1016/j.pop.2021.04.005>
5. Hanneman K., Newman B., Chan F. Congenital variants and anomalies of the aortic arch // *Radiographics.* – 2017. – Vol. 37(1). – P. 32-51. <https://doi.org/10.1148/rg.2017160033>
6. Ramirez Alcantara J., Mendez M.D. Interrupted aortic arch. – Stat. Pearls Publishing, 2023. <https://www.ncbi.nlm.nih.gov/books/NBK532902/>
7. Onalan M.A., Temur B., Aydın S., Suzan D., Demir I.H., Odemis E., Ereğ E. Management of interrupted aortic arch with associated anomalies: a single-center experience // *World J. Pediatr. Congenit. Heart Surg.* – 2021. – Vol. 12(6). – P. 706-714. <https://doi.org/10.1177/21501351211038508>
8. Goldmuntz E. 22q11.2 deletion syndrome and congenital heart disease // *Am. J. Med. Genet.* – 2020. – Vol. 184 (1). – P. 64-72. <https://doi.org/10.1002/ajmg.c.31774>
9. Butensky A., De Rinaldis C.P., Patel S., Edman S., Bailey A., McGinn D.E., Zackai E., Crowley T.B., McDonald-McGinn D.M., Min J., Goldmuntz E. Cardiac evaluation of patients with 22q11.2 duplication syndrome // *Am. J. Med. Genet. A.* – 2021. – Vol. 185 (3). – P. 753-758. <https://doi.org/10.1002/ajmg.a.62032>

10. McDonald-McGinn D.M., Sullivan K.E., Marino B., Philip N., Swillen A., Vorstman J.A., Zackai E.H., Emanuel B.S., Vermeesch J.R., Morrow B.E., Scambler P.J., Bassett A.S. 22q11.2 deletion syndrome // Nat. Rev. Dis. Primers. – 2015. – Vol. 1. – Art. no. 15071. <https://doi.org/10.1038/nrdp.2015.71>
11. Alogab F.W., Almajed M.R., Binsanad N.A., Al Amer S.R., Kalis N.N. Maternal diabetes as a teratogenic factor for congenital heart defects in infants of diabetic mothers // Birth Defects Res. – 2023. – Vol. 115(7). – P. 764-769.
12. Hirano Y., Masuyama H., Hayata K., Eto E., Nobumoto E., Hiramatsu Y. Prenatal Diagnosis of Interrupted Aortic Arch: Usefulness of Three-Vessel and Four-Chamber Views // Acta Med. Okayama. – 2016. – Vol. 70(6). – P. 485-491.
13. Jonas R.A. Management of interrupted aortic arch // Sem. Thorac. Cardiovasc. Surg. – 2015. – Vol. 27. – P. 177-188. <https://doi.org/10.1053/j.semtevs.2015.04.003>
14. Bravo-Valenzuela N.J., Nacif M.S., Araujo Jr. E. Prenatal diagnosis of aortic arch anomalies: Echocardiography, 3D-ultrasonography, and computed tomography angiogram findings. A case report // J. Clin. Ultrasound. – 2021. – Vol. 49(4). – P. 423-427. <https://doi.org/10.1002/jcu.22935>
15. Friedman K. Preoperative physiology, imaging, and management of interrupted aortic arch // Semin. Cardiothorac. Vasc. Anesth. – 2018. – Vol. 22(3). – P. 265-269. <https://doi.org/10.1177/1089253218770198>
16. LaPar D.J., Baird C.W. Surgical considerations in interrupted aortic arch // Semin. Cardiothorac. Vasc. Anesth. – 2018. – Vol. 22(3). – P. 278-284. <https://doi.org/10.1177/1089253218776664>
17. Sanchez Mejia A.A., Cambronero N., Dongarwar D., Salihu H.M., Vigil-Mallete M.A., Garcia B.Y., Morris S.A. Hospital outcomes among infants with interrupted aortic arch with simple and complex associated heart defects // Am. J. Cardiol. – 2022. – Vol. 166. – P. 97-106. <https://doi.org/10.1016/j.amjcard.2021.11.032>
18. Cirillo A., Lioncino M., Maratea A., Passariello A., Fusco A., Fratta F., Monda E., Caiazza M., Signore G., Esposito A., Baban A., Versacci P., Putotto C., Marino B., Pignata C., Cirillo E., Giardino G., Sarubbi B., Limongelli G., Russo M.G. Clinical Manifestations of 22q11.2 Deletion Syndrome // Heart Fail. Clin. – 2022. – Vol. 18(1). – P. 155-164. <https://doi.org/10.1016/j.hfc.2021.07.009>
19. Langley S.M., Sunstrom R.E., Reed R.D., Rekito A.J., Gerrah R. The neonatal hypoplastic aortic arch: decisions and more decisions // Semin. Thorac. Cardiovasc. Surg. Pediatr. Card. Surg. Annu. – 2013. – Vol. 16(1). – P. 43-51. <https://doi.org/10.1053/j.pcsu.2013.01.008>
20. Lopes S.A.V.D.A., Guimarães I.C.B., Costa S.F.O., Acosta A.X., Sandes K.A., Mendes C.M.C. Mortality for Critical Congenital Heart Diseases and Associated Risk Factors in Newborns. A Cohort Study // Arq. Bras. Cardiol. – 2018. – Vol. 111(5). – P. 666-673. <https://doi.org/10.5935/abc.20180175>

Transparency of the study: Authors take full responsibility for the content of this manuscript.

Conflict of interests: Authors declare no conflict of interest.

Financing: Authors declare no financing of the study.

Authors' input: contribution to the study concept – Rakhimzhanova R.I., Dautov T.B.; study design – Moldakhanova Zh.A., execution of the study – Kaliyev B.B., Bastarbekova L.A.; interpretation of the study – Moldakhanova Zh.A.; preparation of the manuscript – Moldakhanova Zh.A., Bastarbekova L.A.

Authors' data:

Moldakhanova Zh.A. (Corresponding author) – M.D., Department of Radiology, National Research Cardiac Surgery Center MOH RK, Astana, the Republic of Kazakhstan, tel. 87716066716, e-mail: moldahanova1991@mail.ru, ORCID ID: <https://orcid.org/0000-0002-5980-9563>;

Rakhimzhanova R.I. – Honored Worker of the RK, Academician of the Academy of Preventive Medicine of the RK, Head of the Department of Radiology No. 1 of JSC "Astana Medical University", Astana, the Republic of Kazakhstan, tel. 87012288058, e-mail: rakhimzhanova01@rambler.ru, ORCID ID: <https://orcid.org/0000-0002-3490-6324>;

Dautov T.B. – Doctor of Science, M.D., Ass. Prof, Head of the Department of Radiology and Nuclear Medicine, Corporate fund "University Medical Center", Astana, the Republic of Kazakhstan, tel. 87077713367, e-mail: tairkhan.dautov@mail.ru, ORCID ID: <https://orcid.org/0000-0002-5267-0108>;

Bastarbekova L.A. – M.D., M.Sc., Department of Radiology, National Research Cardiac Surgery Center MOH RK, Astana, the Republic of Kazakhstan, tel. +77022844036, e-mail: lbastarbekova@mail.ru, ORCID ID: <https://orcid.org/0000-0001-8246-4754>;

Kaliyev B.B. – Head of the Department of Stationary Radiology «National Scientific Center for Mothers and Children» Ministry of Health of the Republic of Kazakhstan, Astana, 010000, the Republic of Kazakhstan, tel. 87014011358, e-mail: baur233113@mail.ru, ORCID ID: <https://orcid.org/0000-0003-4825-749X>;

Address for correspondence: Moldakhanova Zh.A., National Research Cardiac Surgery Center MOH RK, Turan ave. 38, Astana 020000, the Republic of Kazakhstan.